

**AMTE**

## Assessment and Treatment of Vascular Disease and Ulceration

Chuck Gokoo MD, CWS, FACCWS  
Chief Medical Officer  
American Medical Technologies

1

---

---

---

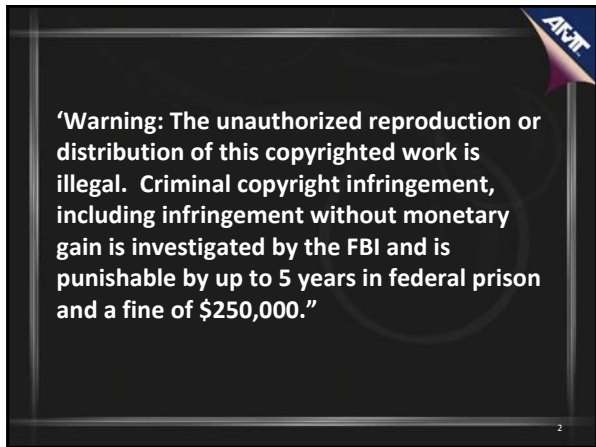
---

---

---

---

---



**AMTE**

**'Warning: The unauthorized reproduction or distribution of this copyrighted work is illegal. Criminal copyright infringement, including infringement without monetary gain is investigated by the FBI and is punishable by up to 5 years in federal prison and a fine of \$250,000.'**

2

---

---

---

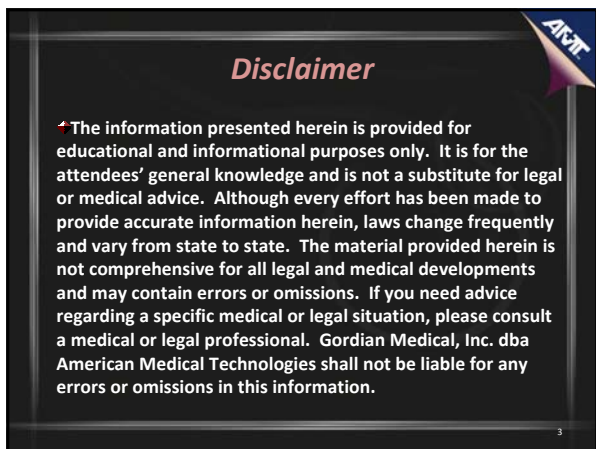
---

---

---

---

---



**AMTE**

### Disclaimer

†The information presented herein is provided for educational and informational purposes only. It is for the attendees' general knowledge and is not a substitute for legal or medical advice. Although every effort has been made to provide accurate information herein, laws change frequently and vary from state to state. The material provided herein is not comprehensive for all legal and medical developments and may contain errors or omissions. If you need advice regarding a specific medical or legal situation, please consult a medical or legal professional. Gordian Medical, Inc. dba American Medical Technologies shall not be liable for any errors or omissions in this information.

3

---

---

---

---

---

---

---

---

## Acknowledgement

- A. D. A. M.
- Association for the Advancement of Wound Care.
- Healthwise Incorporated
- Kim Crosby, PT, CWS

4

---

---

---

---

---

---

---

---

## Objectives

- Explain the pathophysiology of venous and arterial ulcers
- Discuss vascular testing in the diagnosis vascular disease
- Describe the treatment modalities for residents with vascular disease and ulceration

5

---

---

---

---

---

---


---

---

## Vascular Disease

### Venous Leg Ulcers

- 70% of all leg ulcers
- Secondary to underlying venous disease whereby damage to the superficial, deep or perforating veins leads to venous hypertension
- Present within the gaiter region of the leg and are superficial with irregular edges
- The tissue within the ulcer is predominantly viable tissue
- Exudate volumes tend to be moderate to high until the generalized edema throughout the limb is controlled through sustained graduated compression therapy



6

---

---

---

---

---

---

---

---

## Vascular Disease

### Arterial Leg Ulcers

- Result of arterial disease whereby perfusion through the lower limb results in a cycle of tissue damage (ischemia, hypoxia, necrosis) and the development of an ulcer
- Arterial disease is either small vessel or large vessel in origin
- Arterial leg ulcers are usually located from the malleolus (ankle) level down throughout the foot
- They have a uniform edge and present as a cavity
- The base tissue within the wound bed is often non viable or pale




Photo courtesy of Kim Crosby PT, CWS

7

---

---

---

---

---

---

---

---

---

---


---

---

## Vascular Disease

### Mixed Etiology Leg Ulcers

- Origin primarily in the chronic venous insufficiency in the patient's leg and its ability to heal is determined by the severity of the coexisting arterial insufficiency
- It is possible to have both venous and arterial disease at the same time
- Ulcers appear to be of either type, however accurate diagnosis remains vital as compression bandages are rarely suitable if there is significant arterial disease (ABPI<0.8)
- Treatment of mixed ulcers usually focuses on managing the wound, using the approaches described above



8

---

---

---

---

---

---

---

---

---

---

---

---

### Distinguishing Arterial, Diabetic, & Venous Ulcers

Arterial Ulcers	Diabetic Ulcers	Venous Ulcers
<b>Preexisting Factors</b> <ul style="list-style-type: none"> <li>• Peripheral vascular disease (PVD)</li> <li>• Diabetes mellitus</li> <li>• Advanced Age</li> </ul>	<ul style="list-style-type: none"> <li>• Diabetic patient with peripheral neuropathy</li> </ul>	<ul style="list-style-type: none"> <li>• Valve incompetence in perforating veins</li> <li>• History of deep vein thromboses and thrombolysis</li> <li>• Previous history of ulcers</li> <li>• Obesity</li> <li>• Advanced age</li> </ul>
<b>Atypical Location</b> <ul style="list-style-type: none"> <li>• Between toes or tips of toes</li> <li>• Over malleolus</li> <li>• Over phalangeal heads</li> <li>• Around lateral malleolus</li> <li>• All sites subjected to trauma or rubbing of footwear</li> </ul>	<ul style="list-style-type: none"> <li>• On plantar aspect of foot</li> <li>• Over metatarsal heads</li> <li>• Under heel</li> </ul>	<ul style="list-style-type: none"> <li>• On medial lower leg and ankle</li> <li>• On malleolar area</li> </ul>
<b>Wound Characteristics</b> <ul style="list-style-type: none"> <li>• Even wound margins</li> <li>• Deep, pain wound</li> <li>• Bleached or purpuric periwound tissue</li> <li>• Severe pain</li> <li>• Cellulitis</li> <li>• Minimal exudate</li> </ul>	<ul style="list-style-type: none"> <li>• Even wound margins</li> <li>• Deep wound bed</li> <li>• Callus or underlying osteomyelitis</li> <li>• Granular tissue present unless PVD is present</li> <li>• Low to moderate drainage</li> </ul>	<ul style="list-style-type: none"> <li>• Irregular wound margins</li> <li>• Superficial wound bed</li> <li>• Rubby, granular base</li> <li>• Usually no pain</li> <li>• Frequently moderate to heavy exudate</li> </ul>
<b>Pulse Assessment</b> <ul style="list-style-type: none"> <li>• Thin, strong, dry skin</li> <li>• Hair loss on ankle &amp; foot</li> <li>• Thickened toenails</li> <li>• Pallor or cyanosis and dependent rubor</li> <li>• Coolness</li> <li>• Decreased temperature</li> <li>• Absent or diminished pulses</li> </ul>	<ul style="list-style-type: none"> <li>• Diminished or absent sensation in foot</li> <li>• Foot deformities</li> <li>• Palpable pulses</li> <li>• Warm foot</li> <li>• Subcutaneous fat atrophy</li> </ul>	<ul style="list-style-type: none"> <li>• Firm edema</li> <li>• Dilated superficial veins</li> <li>• Dry, thin skin</li> <li>• Evidence of healed ulcers</li> <li>• Periwound and leg hyperpigmentation</li> <li>• Possible dermatitis</li> </ul>

9

---

---

---

---

---

---

---

---

---

---

---

---

## Vascular Disease

### Peripheral Arterial Disease (PAD)

- ~12 million Americans have PAD
- This population is increasing by 1 million individuals/year
- 50-75% individual who have PAD are undiagnosed
- By age 70, 20-30% of the population suffers from PAD
- 150,000 amputations are done per year due to the disease

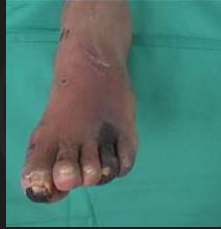

Photo courtesy of Kim Crosby PT, CWS

PARTNERS study, JAMA 2003

10

---

---

---

---

---

---

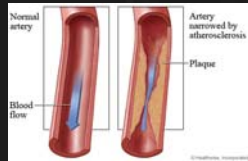
---

---

## Vascular Disease

### Atherosclerosis

- Deposition of cholesterol or triglycerides along the lining of the vessel wall
- Narrowing or total occlusion of the vessel lumen



11

---

---

---

---

---

---

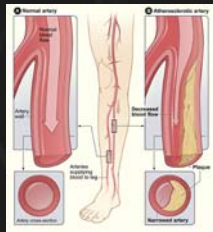
---

---

## Vascular Disease

### Arteriosclerosis obliterans

- Blood vessels in the legs are narrowed or thickened (hardening) due to the loss of elasticity of the arterial wall
- Insufficient tissue perfusion
- Acutely compounded by either emboli or thrombi
- Manifest with:
  - Coronary artery disease
  - Myocardial infarction (MI)
  - Atrial fibrillation
  - Transient ischemic attack
  - Stroke
  - Renal disease



12

---

---

---

---

---

---

---

---

**Vascular Disease**

**Risk Factors**

- \* Genetic predisposition
- \* Aging
  - Age less than 50 years with diabetes, and one additional risk factor (e.g., smoking, hypertension,
  - Age 50 to 69 years and history of smoking , diabetes, hypercholesterolemia, hypertriglyceridemia, hypertriglycemia
  - Age 70 years and older
- \* Abnormal lower extremity pulse examination
- \* Leg symptoms with exertion (claudication) or ischemic rest pain
- \* Known history of atherosclerotic coronary, or renal artery disease

13

---

---

---

---

---

---

---

---

**Vascular Disease**

**History and Physical**

- \* Medical history - including vascular or neurological symptoms
- \* Social history - smoking, ethanol use, exercise, and diet
- \* Height and weight - evaluate for obesity
- \* Blood pressure
- \* Skin exam
- \* Cardiovascular exam
- \* Peripheral pulses
- \* Foot exam - podiatry referral if any abnormalities

14

---

---

---

---

---

---

---

---

**Vascular Disease**

**Patient Functional Status**

- \* Assess assistive devices (i.e. cane, walker, use of motorized cart)
- \* Assess patient's walking ability
  - Distance, pace, balance, shuffled gait, stair climbing
- \* Patient level of activity
  - Given up hobbies or slowed down over the years
- \* Review answers with family members, get their input
- \* May find very different answers!

15

---

---

---

---

---

---

---

---

## Vascular Disease

**Pedal Pulses**

- ✦ Check posterior tibial and dorsalis pedis pulses in both feet
- ✦ Check the palpable temperature of the skin:
  - Heat indicating possible areas of inflammation
  - Coolness indicating areas of possible ischemia



16

---

---

---

---

---

---

---

---

---

---

## Vascular Disease

**Signs and Symptoms**

- ✦ Intermittent claudication
- ✦ Cold feet
- ✦ Nocturnal (rest) pain
- ✦ Absent pulses
- ✦ Paresthesia
- ✦ Atrophy of subcutaneous fat tissue
- ✦ Pale and or shiny skin
- ✦ Absent hair on extremity or foot
- ✦ Thickened nails (fungal infection)
- ✦ Rubor of dependency



Photo: © AAWC, 2008

17

---

---

---

---

---

---

---

---

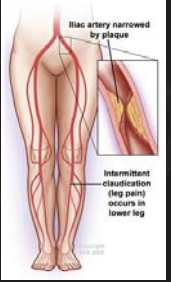
---

---

## Vascular Disease

**Pain**

- ✦ Claudication
  - Calf
- ✦ Rest Pain
  - Inadequate perfusion
  - Night
  - Limb threat
- ✦ Treatment



18

---

---

---

---

---

---

---

---

---

---

## Vascular Disease

**ARJIT**

### Fontaine Classification of PAD (Modified)

Stage	Clinical Detail
I	Objectives signs of PAD without symptoms
IIa	Intermittent claudication, pain free walking distance > 200 m
IIb	Intermittent claudication, pain free walking distance < 200 m
III	Rest pain
IV	Necrotic lesion, gangrene

19

---

---

---

---

---

---

---

---

---



---


## Vascular Disease

**ARJIT**

### Rubor of Dependency

- \* Lower extremity elevation to approximately 45°
- \* Within 60 sec of elevation, skin color changes to pale pallor
- \* Immediately lowering of the lower extremity produces bright red flush called reactive hyperemia (indicative of PAD)



Photos courtesy of Kim Crosby PT, CWS

20

---

---

---

---

---

---

---

---

---

---

## Vascular Disease

**ARJIT**

### Arterial (Ischemic) Ulceration

- \* Accounts for 20% of all leg ulcers
- \* "Punched out" appearance
- \* Ulcer margins clearly demarcated
- \* Location
- \* Ulcer and periulcer tissue characteristics



21

---

---

---

---

---

---

---

---

---

---


## Vascular Disease

**Gangrene**

- ▲ "Dry" gangrene - due to loss of arterial blood supply to the tissue or extremity part
- ▲ "Wet" gangrene - infectious component and requires surgical debridement and/or antimicrobial therapy to control the infection
- ▲ "Fetid foot" - infection involving bone and soft tissue

**Treatment**

- ▲ Debridement of necrotizing fasciitis
- ▲ Vascular reconstruction if possible



Photos courtesy of Kim Crosby PT, CWS

22

---

---

---

---

---

---

---

---

---

---

---

---

## Vascular Disease

**Blue Toe**

- ▲ Cholesterol thrombosis
- ▲ Tissue hypoxia
- ▲ Sudden onset of pain
- ▲ Myalgia
- ▲ Necrosis
- ▲ Gangrene
- ▲ Amputation



23

---

---

---

---

---

---

---

---

---

---


---

---

## Vascular Disease

**Vascular Examination**

- ▲ Invasive procedure
  - Contrast angiography
- ▲ Non-invasive procedures
  - Doppler ultrasound (ABI)
  - Duplex Ultrasonography
  - Magnetic resonance angiography (MRA)
  - TPO2 monitoring
  - Segmental pressures
  - Toe pressures



24

---

---

---

---

---

---

---

---

---

---

---


---

## Vascular Disease

**ARNT**

### Ankle Brachial Index (ABI)

- \* A comparative blood pressure reading in the arm and ankle is used to screen for peripheral arterial disease
- \* A direct measure of fatty plaque buildup in leg arteries
- \* Non-invasive testing
- \* Diagnosis of arterial disease (ischemia)



25

---

---

---

---

---

---

---

---

## Vascular Disease

**ARNT**

### ABI

- \* The doppler closing pressure (brachial pressure) is measured in both arms
- \* Ankle pressure - place the cuff approximately 5 cm above the malleolus
- \* The doppler closing measurements should be taken in the dorsalis pedis and posterior tibial arteries
- \* ABI is 95% sensitive and 99% specific for PAD

### Ischemia Severity

- \*  $>1.2$  - indicates vessel calcification
- \*  $1.0$  - normal
- \*  $0.7 - 0.9$  - mild ischemia
- \*  $0.4 - 0.7$  - moderate ischemia
- \*  $<0.4$  - severe ischemia

26

---

---

---

---

---

---

---

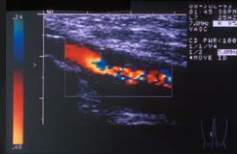
---

## Vascular Disease

**ARNT**

### Duplex Ultrasonography

- \* Arterial and Venous disease
- \* Sensitivity of 80% and a specificity of 90-100% for detecting femoral and popliteal disease
- \* Sensitive and specific (90-100% in most series) for detecting proximal deep vein thrombosis
- \* A reverse flow can be identified by color code



27

---

---

---

---

---

---

---

---

## Vascular Disease

### Color Duplex Scanning

#### Arterial

- Identify obstructive atherosclerotic disease
- Carotid
- Renal
- Surveillance of infrainguinal bypass grafts
- Surveillance of lower limb arteries after angioplasty

#### Venous

- Diagnosis of deep vein thrombosis above the knee
- Assessing competence of valves in deep veins
- Superficial venous reflux
- Identify and locate reflux at saphenopopliteal junction
- Assessing st with recurrent varicose veins
- Preoperative mapping saphenous vein

28

---

---

---

---

---

---

---

---

---

---

## Vascular Disease

### Vascular Reconstruction

#### Indications include:

- Rest pain
- Nocturnal pain
- Non responding foot ulcer
- Non responding infection
- Incipient gangrene
- Intermittent claudication

#ADAM

29

---

---

---

---

---

---

---

---

---

---

## Vascular Disease

### Balloon Angioplasty

- Non surgical procedure
- Dilatation of narrowed or occluded arteries

### Stenting

- Cylindrical mesh tube is expanded in the artery

30

---

---

---

---

---

---

---

---

---



---

## Vascular Disease

**ARNT**

**Hyperbaric Oxygen Therapy (HBO)**

- + 100% oxygen inspired under pressure
- + Therapeutic Affects
  - Counteracts ischemia and hypoxia
  - Increased oxygen diffusion to the tissue
  - Increased angiogenesis
- Use is limited by amount of limb ischemia

31

---

---

---

---

---

---

---

---

---

---

## Vascular Disease

**ARNT**

**PAD and Diabetes Mellitus (DM)**

- + With each 1% ↑ HgbA1c there is 28% ↑ in PAD risk
- + Strong associated of DM with femoral-popliteal and tibial artery disease
- + Recent survey of ABI results found 20% prevalence of PAD in diabetics > age 40 and 29% in those > 50yrs (Elhadd TA et al, Practical Diabetes 1999)
- + American Diabetes Association recommends patients with DM have an ABI done annually

32

---

---

---

---

---

---

---

---

---


---

## Vascular Disease

**ARNT**

**Reducing Amputation**

- + 49% and 85% of all amputations can be prevented
- + Use of a multidisciplinary team
  - Annual inspection of the foot
  - Identification of the foot at risk
  - Education of people with diabetes and healthcare professionals
  - Appropriate foot wear
  - Rapid treatment of all foot problems



33

---

---

---

---

---

---

---

---


---

---



## Vascular Disease

- ✦ **Pigmentation**
  - Brown discoloration of the skin
  - Leakage of RBC's into tissue
  - Hemoglobin breaks down to hemosiderin
- ✦ **Ulceration**
  - Vary in size
  - Gaiter area (Malleolus)
- ✦ **Lipodermatosclerosis**
  - Thickening in the tissues underneath the skin
  - Hard and woody
  - Loss of normal suppleness



37

---

---

---

---

---

---

---

---

---

---

## Vascular Disease

**Varicose eczema**


- Skin becomes red, wet and scaly
- skin can appear very angry and inflamed

**"Inverted champagne bottle"**

- Narrow at the ankle and just above
- Increased girth in the upper part of the calf below the knee
- Pigmentation around the ankle and sometimes with varicose veins

**Edematous**

- Swelling around the ankle, foot and lower leg
- Mild to severe



38

---

---

---

---

---

---

---

---

---

---

## Vascular Disease

### Venous Insufficiency Classification

- ✦ **C Clinical signs: (0 - 6), supplemented by (A) for asymptomatic and (S) for symptomatic patients**
  - Class 0 No visible or palpable signs of venous disease
  - Class 1 Telangiectasias or reticular veins
  - Class 2 Truncal varicose veins and their branches
  - Class 3 Edema
  - Class 4 Skin changes ascribed to venous disease (e.g., pigmentation, stasis eczema, dermatoliposclerosis)
  - Class 5 Skin changes as defined above with healed ulceration
  - Class 6 Skin changes as defined above with active ulceration
- ✦ **E Etiology classification: congenital, primary, secondary**
- ✦ **A Anatomic distribution: superficial (S), deep (D), or perforating veins (P), or combinations**
- ✦ **P Pathophysiologic dysfunction: reflux or obstruction, alone or in combination**

39

---

---

---

---

---

---

---



---

---

---

**ARNT**

## Vascular Disease

C(2) E(p) A(s, p) P(r)

C(4) E(p) A(s, p) P(r)

40

---

---

---

---

---

---

---

---

---


---

**ARNT**

## Vascular Disease

### Compression Therapy

- Produce local alteration of microvascular hemodynamics
- Enables the pump mechanism to effectively reduce venous hypertension
- Reduction of edema and/or ulcer healing
- Investigation to determine if insufficiency can be corrected by surgery or endovenous repair



41

---

---

---

---

---

---

---

---

---

---

**ARNT**


## Vascular Disease

### Indication

- Chronic Venous Insufficiency
- Ulcer treatment
- Deep Vein Thrombosis (DVT)
- Superficial Thrombophlebitis
- Sclerotherapy/surgery of varicose veins

### Contraindication

- Arterial Insufficiency
- ABI <0.6
- Absolute ankle arterial pressure <65mmHg



42

---

---

---

---

---

---

---

---


---

---

## Vascular Disease

**Ambulation**

- Walking not standing is required for calf muscle/pump function
- Exerts pressure equal to the distending pressure generated by calf-muscle contraction
- Counter force returns microcirculation to a more normal state
- Augmentation of venous emptying



43

---

---

---

---

---

---

---

---


---

---

## Vascular Disease

**Thromboangiitis obliterans (Buerger's disease)**

- Autoimmune disease associated with smoking
- Combination of acute inflammation and thrombosis (clotting) of the arteries and veins in the hands and feet
- The obstruction of blood vessels in the hands and feet reduces the availability of blood to the tissues, causes pain and eventually damages or destroys the tissue
- Skin ulcerations and gangrene of fingers and toes
- No cure for Buerger's disease



44

---

---

---

---

---

---

---

---


---

---

## Vascular Disease

**Symptoms in the hands and feet include:**

- Enlarged, red, tender cord-like veins
- Pain or tenderness
- Numbness and tingling
- Skin discoloration
- Skin ulcers or gangrene of the fingers/toes
- Worsen with exposure to cold or emotional stress
- Two or more limbs affected
- Pain increases with activity such as walking and decreases with rest
- Pulse may be decreased or absent in the affected extremity



45

---

---

---

---

---

---

---

---

---

---

## Vascular Disease

**Diagnosis**

- Allen test
- Angiogram or an arteriogram of the upper and lower extremities
- Doppler ultrasound



46

---

---

---

---

---

---

---

---

---

---

## Vascular Disease

**Treatment**

- Immediate smoking cessation
- Patients who continue to smoke after a diagnosis of Buerger's disease will generally require amputation of the fingers and toes
- The goal of treatment to control symptoms includes:
  - Avoiding conditions that reduce circulation to the extremities, such as cold temperatures)
  - Avoid sitting or standing in one position for long periods
  - Do not walk barefoot (to prevent injury)
  - Do not wear tight or restrictive clothing
  - Report all injuries to your physician for appropriate treatment

47

---

---

---

---

---

---

---

---

---

---

## Vascular Disease

**In Closing**

- Ulcers arise from a number of causes, and their presentation and clinical course will vary according to the cause
- Being able to differentially diagnose ulcers is important when considering the choice and implementation of treatment as they will differ

48

---

---

---

---

---

---

---

---

---

---

**For more information about this presentation or other educational activities, please contact [info@amtwoundcare.com](mailto:info@amtwoundcare.com)**



49

---

---

---

---

---


---

---

---

**References**

- ♣ Kingsley A. (2001) A Proactive approach to wound infection. *Nursing Standard*. 15(30):50-58.
- ♣ Niezgoda JA, Mewissen M, The Management of Lower Extremity Wounds Complicated by Acute Arterial Insufficiency and Ischemia. *Wounds May 2004, 50 (5A) Supplement*.
- ♣ Sieggreen M. Y., Kline R. A., Arterial Insufficiency and Ulceration: Diagnosis and Treatment Options. *Adv Skin wound Care 2004;17:242-51*.
- ♣ Bonham PA, Flemister BG, Goldberg M, Crawford PE, Johnson JJ, Vernado MF, What's New in Lower Extremity Arterial Disease. *Wound Ostomy Continence Nurs.* 2009;36(1):37-44.



50

---

---

---

---

---

---

---

---

**References**

- [www.pad.org](http://www.pad.org)
- [www.PADCoalition.org](http://www.PADCoalition.org)
- [www.mayoclinic.com/.../peripheral-arterial-disease/ds00537](http://www.mayoclinic.com/.../peripheral-arterial-disease/ds00537)



51

---

---

---

---

---

---

---

---

**ARNT**

## Definitions

- ✦ **Arterial Ulcer** - an ulceration that occurs as the result of arterial occlusive disease when non-pressure related disruption or blockage of the arterial blood flow to an area causes tissue necrosis.
- ✦ **Atherosclerosis** - a process of progressive thickening and hardening of the walls of medium-sized and large arteries as a result of fat deposits on their inner lining.
- ✦ **Angiography** - the initial technique of percutaneous coronary intervention, coronary angioplasty, was to widen narrowed coronary arteries by inflating a small balloon catheter at the site of the narrowing.
- ✦ **Buerger's disease** - an inflammation of the arteries, veins, and nerves in the legs, principally, leading to restricted blood flow. Left untreated, Buerger's disease can lead to gangrene of the affected areas. Buerger's disease is also known as thromboangitis obliterans.

52

---

---

---

---

---

---

---

---

**ARNT**

## Definitions

- ✦ **Gangrene** - the decay or death of an organ or tissue caused by a lack of blood supply. It is a complication resulting from infectious or inflammatory processes, injury, or degenerative changes associated with chronic diseases, such as diabetes mellitus.
- ✦ **Intermittent claudication** - an aching, cramping, tired, and sometimes burning pain in the legs that comes and goes. It typically occurs with walking and goes away with rest. Due to poor circulation of blood in the arteries of the extremities.
- ✦ **Peripheral artery disease** - a form of peripheral vascular disease in which there is partial or total blockage of an artery, usually one leading to a leg or arm.
- ✦ **Plaque** - the lesion of atherosclerosis, a pearly white area within an artery that causes the intimal surface to bulge into the lumen; it is composed of lipid, cell debris, smooth muscle cells, collagen, and in older persons, calcium.

53

---

---

---

---

---

---

---

---