

Tickborne Powassan Virus Infections Among Wisconsin Residents

Diep K. Hoang Johnson, BS; J. Erin Staples, MD; Mark J. Sotir, PhD MPH;
David M. Warshauer, PhD; Jeffrey P. Davis, MD

ABSTRACT

Introduction: Powassan virus (POWV) is a tickborne *Flavivirus* that causes a rare but potentially life-threatening illness. The first reported case of POWV infection in a Wisconsin resident occurred in 2003. Enhanced surveillance and testing detected 2 additional cases.

Methods: Patient specimens with a positive or equivocal immunoglobulin M (IgM) antibody to an arbovirus were sent from commercial laboratories to the Wisconsin State Laboratory of Hygiene and forwarded to the Centers for Disease Control and Prevention (CDC) for confirmatory testing. Patients with laboratory confirmed POWV infections were interviewed to obtain demographic, clinical, and epidemiologic information.

Results: POWV infections were confirmed in 3 adult Wisconsin residents in 2003, 2006, and 2007; illness onsets occurred during May and June. Two patients were hospitalized and all survived. One patient had a dual infection with POWV and *Anaplasma phagocytophilum*. Specimens from all 3 patients were initially reported as positive for IgM antibody to either St Louis encephalitis or California serogroup viruses; POWV-specific antibody was detected during confirmatory testing at the CDC. Each patient had exposures to known or likely tick habitats in different counties within 30 days before illness onset.

Conclusions: These are the first diagnosed human POWV infections in Wisconsin. Because all 3 patients were initially identified as having other arboviral infections using commercial screening kits, routine confirmatory testing is essential for proper diagnosis of most arboviral infections. Wisconsin residents should be educated regarding risks of acquiring and ways to prevent POWV infection and other tickborne diseases when spending time outdoors.

INTRODUCTION

Powassan virus (POWV) is an arthropod-borne virus (arbovirus) in the family of *Flaviviridae*, genus *Flavivirus*. Human POWV infections are rare and associated with acute onset of fever, profound muscle weakness, confusion, headache, nausea, vomiting, and stiff neck. Severe signs and symptoms include respiratory distress, tremors, seizures, paralysis, and coma.¹⁻³ Most individuals with POWV infections develop meningoencephalitis and many have long-term neurologic sequelae; 10%-15% of cases are fatal.³⁻⁵ POWV is transmitted to humans through the bite of an infected tick. Symptoms usually begin at least 1 week (range 8-34 days) following infection.² Apart from supportive and symptomatic management, there are no specific treatments for or vaccines available to prevent POWV infection.

Initially isolated in 1958 from the brain of a boy aged 5 years who developed encephalitis and died, POWV was named after the northern Ontario town where the child resided.⁵ The first POWV infection reported in the United States occurred in New Jersey in 1970. Since then, POWV infections have been reported rarely and have occurred in Maine, Michigan, Minnesota, New York, Vermont, and Wisconsin.⁶⁻⁷

POWV has been isolated from several North American tick species, including *Ixodes spp.* (*I. cookei*, *I. marxi*, and *I. spinipalpus*) and *Dermacentor andersoni*.⁵ In Wisconsin, a POWV variant, deer tick virus (DTV), has been isolated from *I. scapularis*.⁸⁻¹⁰ Presence

Author Affiliations: Bureau of Communicable Diseases and Emergency Response, Wisconsin Division of Public Health, Madison, Wis (Hoang Johnson, Sotir, Davis); Division of Vector-Borne Infectious Diseases, Centers for Disease Control and Prevention, Fort Collins, Colo (Staples); Division of Communicable Diseases, Wisconsin State Laboratory of Hygiene, Madison, Wis (Warshauer); Division of Foodborne, Bacterial, and Mycotic Diseases, Centers for Disease Control and Prevention, Atlanta, Ga (Sotir).

Corresponding Author: Diep K. Hoang Johnson, BS, Bureau of Communicable Diseases and Emergency Response, Wisconsin Division of Public Health, 1 W Wilson St, Rm 318, Madison, WI 53701-2659; phone 608.267.9000; fax 608.261.4976; e-mail diep.hoangjohnson@wi.gov.

Table 1. Council of State and Territorial Epidemiologists and Centers for Disease Control and Prevention Case Definition of Powassan Virus (POWV) Infection¹³

Confirmed case

A clinically compatible illness in an individual with specific laboratory criteria supporting the diagnosis. Clinically compatible illness includes a febrile illness with headache, myalgia, arthralgia, and may be accompanied by skin rash or lymphadenopathy or central nervous system disease (meningitis or encephalitis).

Laboratory criteria (1 of the following)

- Four-fold or greater change in virus-specific serum POWV antibody titer
- POWV-specific IgM antibodies demonstrated in CSF
- POWV-specific IgM antibody demonstrated in serum and POWV-specific neutralizing antibody in the same serum or a later specimen (if other arbovirus is also detected, POWV titer must be at least 4-fold higher than the titer corresponding with the other arbovirus agent)
- Detection of POWV in culture or viral RNA by nucleic acid testing

of POW-lineage viruses has been well documented in at least 38 mammal species including small- and medium-sized wild animals (rodents, woodchucks, skunks) and domestic animals (dogs, cats).⁵

Following the introduction of West Nile virus (WNV) to the United States in 1999, federal funding to establish WNV surveillance through cooperative agreements with the Centers for Disease Control and Prevention (CDC) enabled states to detect and report arboviral infections. In 2001, the Wisconsin Division of Public Health (WDPH) expanded arbovirus-related human case surveillance statewide and collaborated with the Wisconsin State Laboratory of Hygiene (WSLH) to implement arbovirus panel testing for West Nile, La Crosse (LAC), St Louis encephalitis (SLE), Eastern equine encephalitis (EEE), and Western equine encephalitis (WEE) viruses. In 2003, the list of notifiable arbovirus diseases in the United States was expanded to include WNV, POW, SLEV, EEE, WEE, and California (CAL)-serogroup (LAC and other CAL) viruses.¹¹ In Wisconsin, all arbovirus infections are reportable.¹²

Herein we describe enhanced arbovirus surveillance methods that resulted in detection of POWV infections in 3 Wisconsin residents from 2003 through 2007, and we provide clinical and laboratory information, and findings of the epidemiologic investigations of each case.

METHODS

Cases of POWV infection were defined using the Council of State and Territorial Epidemiologists and

the CDC arboviral infection case definition adapted for POWV infection (Table 1).¹³

Laboratory Testing

Commercially available laboratory tests for arboviruses may produce false-positive and cross-reactive results. Given this, WDPH requests all samples that are immunoglobulin M (IgM) positive at a commercial lab be sent to WSLH for confirmatory testing. Arboviral testing (WN, SLE, LAC, EEE, and WEE) at WSLH is performed by applying an algorithm on serum and cerebrospinal fluid (CSF) specimens using a sensitive IgM capture enzyme-linked immunoabsorbent assay (MAC-ELISA) and then using a more specific plaque-reduction neutralization test (PRNT) for confirmation.¹⁴ All specimens with positive or indeterminate WSLH test results were forwarded to the Arboviral Diagnostic Laboratory (ADL) at the CDC for additional confirmatory testing, including PRNTs. With PRNT, the patient's serum (ie, antibodies) is combined with a live virus. If the antibodies are specific to the virus, a complex is formed and this prevents the infection of Vero cells and a reduction in the number of plaques formed when the Vero cells are combined with the virus. To determine the likely etiology of the infection, ADL staff employed a regional algorithm method using IgM MAC-ELISA, immunoglobulin G (IgG) ELISA, IgM microsphere immunoassay (MIA), and PRNT testing for the following arboviruses: CAL, LAC, EEE, SLE, WEE, WN, Jamestown Canyon (JC), and POW.

Epidemiologic Investigation

Patients with illnesses meeting the case definition for POWV disease were interviewed by local health department investigators using a standard arbovirus follow-up form that included questions on demographic features, clinical information, travel history, mosquito, or other vector exposures, the use of insect repellent during the 2 weeks before illness onset, and received or donated blood or organs within 30 days before illness onset. Completed forms were sent to the WDPH; information was entered into an electronic database and reported to the CDC via ArboNET, a national electronic surveillance reporting system for arboviruses.

RESULTS

Patient 1: 2003

This patient's illness was previously described in brief.⁶ A 69-year-old man who resided in Rusk County saw his physician on June 26, 2003, with an 11-day history of nausea and epigastric and right upper quadrant pain; a proton pump inhibitor was prescribed. The abdomi-

Table 2. Results of Arbovirus Testing at the Wisconsin State Laboratory of Hygiene (WSLH) and the Centers for Disease Control and Prevention (CDC) of Specimens Obtained from Patients with Powassan Virus (POWV) Infection, Wisconsin, 2003-2007

Patient	Collection Date	Specimen Type	WSLH Results	CDC Results	Interpretation of Results
Patient 1	07/09/2003	Serum	SLEV IgM+	POWV IgM+ POWV IgG+ POWV PRNT+ (1:320)	Serologic evidence of recent POWV infection; cross-reactive SLEV antibodies
	07/10/2003	CSF	IgM equivocal to SLEV	POWV IgM+	
Patient 2	07/10/2006	Serum	SLEV IgM ^a	POWV IgM+ POWV IgG+ POWV PRNT+ (1:20) LACV PRNT+ (1:10) JCV ^b PRNT+ (1:80)	Serologic evidence of a recent POWV infection and previous CAL serogroup bunyavirus
	07/16/2006	Serum	SLEV IgM ^a	POWV IgM+ POWV IgG+ POWV PRNT+ (1:80) LACV PRNT+ (1:20) JCV ^b PRNT+ (1:80)	
	08/03/2006	CSF	SLEV IgM ^a	not tested	
Patient 3	06/20/2007	Serum	arbovirus negative	POWV IgM+ POWV IgG+ POWV PRNT+ (1:80)	Serologic evidence of a recent POWV infection; non-specific CALV reactivity
	08/10/2007	Serum	LACV IgM equivocal	POWV IgM+ POWV IgG+ POWV PRNT (1:80)	

Abbreviations: SLEV, St Louis encephalitis virus; POWV, Powassan virus; CALV, California serogroup virus; LACV, La Crosse virus; JCV, Jamestown Canyon virus; PRNT, serum dilution-plaque reduction neutralization test; CSF, cerebrospinal fluid

^a Indeterminate result: non-specific reactivity to West Nile virus.

^b There are no IgM and IgG tests for JCV in the United States; antibody testing is done using only PRNT at the CDC.

nal pain improved. On June 27, he developed recurring chills and fever and was hospitalized on July 8. Significant findings included temperature 101.7°F and a heart murmur; echocardiogram (echo) was normal. Hematologic laboratory abnormalities included hemoglobin 11.5 g/dL and platelets 82,000/mm³. Cerebrospinal fluid (CSF) obtained on July 9 was clear, colorless with white blood cell count (WBC) 60/mm³, red blood cell count (RBC) 73,080/mm³, glucose 75mg/dL, and protein 60mg/dL. Multiple blood cultures were negative. Given the correlation between anemia, thrombocytopenia, and some tickborne infections, blood specimens obtained on July 9 and July 10 were tested for IgM and IgG antibodies to *Anaplasma*, *Borrelia burgdorferi*, and arboviruses. *Anaplasma morulae* were detected in a blood smear, serologic tests demonstrated a positive (512) *Anaplasma* titer and an equivocal SLEV titer. The patient began treatment on July 9 with doxycycline (100 mg bid for 21 days). Discharge diagnoses on July 11 indicated a febrile illness with *Anaplasma* and an arbovirus as suspected pathogens. Tests of a serum specimen obtained on July 24 demonstrating an *Anaplasma* titer ≥512 confirmed the *Anaplasma* infection.

Given the equivocal SLEV IgM results from the hospital testing, the patient's serum and CSF were forwarded to the WSLH and arbovirus IgM panel testing yielded positive and equivocal results to SLEV, respectively (Table 2). Arboviral testing of both specimens at the CDC demonstrated positive POWV-specific IgM, IgG, and neutralizing antibodies. There was no evidence of neutralizing antibodies to SLEV, which suggested the antibody to SLEV detected at the hospital laboratory and the WSLH was a result of *Flavivirus* cross-reactivity. Diagnostic testing of this patient confirmed a dual infection with *Anaplasma phagocytophilum* and POWV.

During an interview on July 21, 2003, the patient reported persistent lethargy but no other signs or symptoms of neurologic illness before or after hospital discharge. He reported exposure to areas with ticks and small mammals within 20 days prior to illness onset; exposure was mostly in his yard and in woods near his home (Figure 1). He also traveled to northwest Ontario, Canada to fish in a wooded area during June 23-25. He reported no known tick bites before illness onset. Because the incubation periods for both anaplasmosis

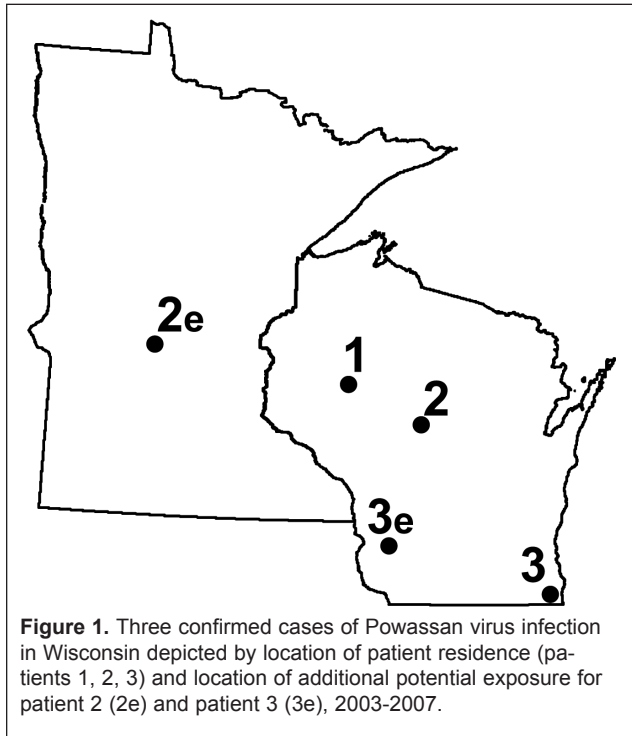


Figure 1. Three confirmed cases of Powassan virus infection in Wisconsin depicted by location of patient residence (patients 1, 2, 3) and location of additional potential exposure for patient 2 (2e) and patient 3 (3e), 2003-2007.

and POWV infection exceed 1 week, infection with POWV and *Anaplasma* likely occurred near his home between June 12 and June 19.

Patient 2: 2006

On July 3, 2006, a 49-year-old man who resided in Marathon County presented at a clinic with fever, chills, headaches, myalgia, and fatigue that began June 29. He reported congestion, mild non-productive cough, and a history of smoking (33 pack years). Physical examination was unremarkable. Laboratory findings included mildly elevated WBC (12,600 cells/mm³) and creatinine (1.1 mg/dL). Computed tomography (CT) scans of the chest and head were negative. The patient was diagnosed with a fever of unknown etiology and was prescribed clarithromycin.

On July 4, the patient was seen at an emergency department (ED) with throbbing frontal headache with bitemporal radiation, fever (103.8°F), chills, malaise, fatigue, photophobia, nausea, stiff neck, muscle aches, and loss of appetite and was admitted to a hospital. Admission temperature was 102.9°F, blood pressure 157/70 mm. No additional abnormalities were detected during physical examination. Chest x-ray was normal; lumbar puncture was not performed. Laboratory testing results included WBC 8500/mm³ with 76% granulocytes. The differential diagnosis included a zoonotic infection and aseptic meningitis. Results of tests conducted at the hospital laboratory for *Borrelia burgdor-*

feri, *Anaplasma*, and Rocky Mountain spotted fever were negative; WNV ELISA testing was inconclusive. The patient was treated with doxycycline (100 mg bid for 14 days), albuterol, and hydrochlorothiazide. Within 3 days, his appetite improved, chills and headaches resolved, myalgia decreased, and he walked without unsteadiness or weakness. Laboratory results returned to normal. He was discharged July 10 with diagnoses of viral syndrome with meningoencephalitis and clinical depression.

Several days later, the patient developed general malaise, decreased appetite, photophobia, and chills. He was hospitalized July 16 for evaluation of viral encephalitis, decreased appetite, dehydration, and acute renal failure. Laboratory test results included creatinine 3.6 mg/dL and blood urea nitrogen (BUN) 77 mg/dL. While hospitalized, he received supportive treatment for dehydration and physical therapy; his laboratory and clinical status soon improved. Repeated laboratory tests of specimens obtained July 10 and July 16 for *Anaplasma*, *Borrelia burgdorferi*, and WNV were negative; tests of both specimens at the WSLH demonstrated positive IgM antibodies to SLEV. Discharge diagnoses on July 20 included acute renal failure secondary to dehydration, and viral encephalitis, presumptively SLE.

A CSF sample was obtained August 3 to confirm the SLE antibody positive results. Arbovirus testing at WSLH of 2 sera and a CSF sample demonstrated positive results for IgM antibody to SLEV; WNV results were indeterminate (Table 2). Testing of serum specimens at the CDC revealed positive IgM and IgG antibody to POWV with a 4-fold change (PRNT 20-80) in antibody titers indicative of recent POWV infection. Additional specific antibody tests indicated cross-reacting antibodies to SLEV and negative tests for other arboviruses. Prior infection with a California serogroup virus was also detected. The CSF sample was not available for CDC testing.

During an August 21 interview, the patient reported persistent thigh and back weakness, shoulder pain, memory deficit, gait and balance difficulty, and depression. He recalled noting a rash on his back 1 week before illness onset. He resided in a heavily wooded area in Marathon County (Figure 1). Activities included camping trips to a lake in Marathon County (north-central Wisconsin) on June 4 when he observed deer ticks on his dog and recalled being bitten by a tick, to St Cloud (central Minnesota) from June 16 to June 18, and to a park in Price County (northern Wisconsin) from June 23 to June 24 where he received many mosquito bites.

The exposure to POWV likely occurred in Marathon County near his home or in Minnesota from June 15 to June 22.

Patient 3: 2007

A 47-year-old woman who resided in Kenosha County was evaluated June 15, 2007, 2 days after onset of generalized aches, nausea, and lightheadedness and 25 days after noticing a rash on her neck and onset of severe headaches. Because of prior history of migraine headaches, she delayed seeing a physician. Her headaches were treated with analgesics but did not improve. On June 20, she experienced persistent headaches and blurred vision. She had recent cataract surgery. Results of laboratory tests on June 20 included WBC 6000/mm³ and platelets 160,000/mm³ and were otherwise unremarkable. A serum specimen sent to a commercial laboratory was tested for antibodies against arboviruses, *Anaplasma*, *Borrelia burgdorferi*, CMV, EBV, lymphocytic choriomeningitis virus, rubella, rubeola, VZV, and HSV types 1 and 2. Results received on June 26 were positive for IgM antibody to CALV and negative for IgG. WNV IgM result was inconclusive due to high background reactivity, and WNV IgG was negative. The patient was referred to her ophthalmologist for evaluation of abnormal vision.

The patient was seen again in an ED June 29 following complaints of upper respiratory tract symptoms and shortness of breath; the patient denied chest pain, orthopnea, fever, cough, or gastrointestinal complaints. Physical examination, electrocardiogram, and chest x-ray were normal. She was treated with albuterol and discharged. During a follow-up interview July 10, the patient complained of memory deficit, and neck and back pain.

Arboviral testing at the WSLH of the June 20 serum specimen was negative, but because of the positive IgM result for CALV at the commercial laboratory, the sample was sent to the CDC. CDC testing identified IgM and IgG antibodies against POWV and a PRNT of 80 (Table 2). A serum specimen obtained August 10 and tested at the WSLH demonstrated equivocal IgM antibody to LACV and confirmatory testing at the CDC identified IgM and IgG antibodies against POWV with PRNT of 80 (Table 2). This result suggested a recent infection with POWV and a false-positive IgM antibody to CALV as subsequent testing did not detect IgM nor IgG antibodies to CALV.

The patient resided in southeastern Wisconsin but went turkey hunting in Vernon County (southwestern Wisconsin) during weekends in May (Figure 1). She reported sitting on the ground in grassy and brushy

areas where many small mammals were seen including skunks and squirrels. She had no known tick bites and did not use repellent with *N,N*-Diethyl-*meta*-toluamide (DEET) while turkey hunting. She denied travel outside of Wisconsin. Exposure to POWV most likely occurred in Vernon County from May 6 to May 13, assuming her illness onset was May 20 when she developed severe headaches.

DISCUSSION

As with other arboviruses, asymptomatic infections with POWV can occur.⁵ Symptomatic infections typically present as encephalitis or meningitis and often result in significant morbidity and mortality. Symptoms of POWV infection can be difficult to differentiate from those caused by other arboviruses. In the United States and Canada, POWV infections are less frequently reported than infections with other arboviruses that cause encephalitis, namely WNV, LACV, SLEV and EEEV.^{1,15} It is uncertain whether the small number of cases reported is related to limited disease activity, awareness, testing, or surveillance. Our surveillance suggests POWV infection is likely to be misdiagnosed and thus under-reported in Wisconsin.

From 1958 to 2007, 44 POWV illnesses have been identified in North America—28 in the United States, and 16 in Canada.^{2,6,16} Before 1999, most cases occurred in Northeastern United States and Eastern Canada. During 1999-2007, 17 POWV infections reported in the United States occurred in Maine (4 cases), New York (8), Michigan (1), Vermont (1), and Wisconsin (3).^{6,16} The most recent cases occurred in New York state in 2008 and in Minnesota in 2008 and 2009.¹⁶⁻¹⁷

Most commercial assays for arboviruses are labeled for use on serum to aid in a presumptive diagnosis, and further testing is recommended to confirm the results.¹⁸ The 3 Wisconsin cases were detected using an enhanced statewide surveillance that ensures confirmatory tests are conducted at the WSLH and as needed at the CDC on all specimens testing positive for arboviruses at commercial laboratories. In our 3 cases, initial tests incorrectly identified a non-Powassan arbovirus as the infectious agent. Confirmatory tests demonstrated specimens from 2 patients were serologically cross-reactive to SLEV and 1 patient had a false-positive result to CALV. In all cases, more specific testing for the presence of neutralizing antibody using PRNT was needed to properly diagnose POWV infection. Physicians should consider requesting additional confirmatory testing on their patient samples that test positive for an arboviral agent on a commercial assay.

The 3 Wisconsin patients were adults (age range 47-69 years), 2 were males, and all 3 had illness onsets in late May and June. Two patients were hospitalized, with 1 requiring rehospitalization. All 3 resided in wooded areas or traveled to forested areas 7-14 days before illness onset and had other possible tick exposures within 30 days before onset.

One patient was co-infected with *Anaplasma phagocytophilum*, which is endemic in Wisconsin. The highest incidence of anaplasmosis in Wisconsin occurs in the northwestern counties. About 810 cases of anaplasmosis were reported in Wisconsin during 2003-2007. *Anaplasma* are transmitted by *I. scapularis* (deer ticks or blacklegged ticks). Human co-infection with multiple tick pathogens occurs when a deer tick harboring these agents feeds on the host. Illness onset with anaplasmosis usually occurs 5-14 days (median 9 days) after being bitten by an infected tick. Common symptoms of anaplasmosis include chills, fever, headache, and myalgia, which are similar to symptoms of arbovirus infections. However, clinical laboratory findings include thrombocytopenia, elevated hepatic transaminase, leukopenia, and anemia. Intracytoplasmic bacterial aggregates (morulae) present in leukocytes can be useful in the diagnosis of *Anaplasma* infection.¹⁹ In addition, laboratory tests such as culture and isolation of the organism, immunostaining of antigen in a skin biopsy, serologic testing for antibodies, and polymerase chain reaction (PCR) assay are also important for differential diagnosis. While anaplasmosis was diagnosed initially in patient 1, the systematic testing for multiple agents was essential to detect the co-infection with 2 tickborne pathogens.

Infection with POWV has been described as most closely related to the tickborne encephalitis (TBE) virus, which causes significant neurologic disease and is endemic in Eastern Europe and part of Asia.²⁰ However, 2 of the Wisconsin POWV infections were relatively mild illnesses compared to other POWV infections. One possible explanation for the mild illness may involve infection with the deer tick virus (DTV). Identified in 1997, DTV was found to be a genotype of POWV.²¹⁻²² Further studies suggest DTV and POWV strains in North America are divided into 2 distinct lineages.^{8,23} Lineage 1 strains, such as POWV, are suspected to be more pathogenic and associated with the tick species *I. cookei* and in turn with groundhogs; these strains have typically been isolated in New York and Canada.⁸ Lineage 2 strains, such as DTV, are associated with *I. scapularis* and have been isolated from adult ticks collected near

Spooner, Wis.¹⁰ However, current antibody testing cannot differentiate DTV from POWV infections. To date, the only 2 known human DTV infections were documented based on post-mortem retrieval of DTV from neurologic tissues.²⁴

Experimental transmission studies suggest mice can acquire POWV from infected nymph-phase deer ticks within 15 minutes;²⁵ it is not known how brief tick attachment must be to transmit POWV to humans or the minimum viral load required for symptomatic POWV infection.

It is important for clinicians and the public to be aware that in Wisconsin, *I. scapularis* is the most likely vector to transmit tickborne pathogens that cause anaplasmosis, babesiosis, Lyme disease, and POWV/DTV infections. The key to preventing tickborne infections is to avoid the habitats of rodents where ticks are most likely to reside. Tick bite prevention includes avoiding tick infested areas (wooded areas with tall grass, weeds, leaf litter) and taking precautions when entering wooded areas. Precautions include wearing proper clothing, tucking shirts into pants and pants into socks to create a barrier against ticks, checking for ticks on oneself and pets after being outdoors, and using tick repellents. Environmental control measures to minimize tick encroachment include use of landscaping and actions that discourage wild animals from nesting near homes. Finally, in Wisconsin it is important for clinicians and laboratories to consider vectorborne arboviral diseases in the differential diagnosis of springtime and summertime illnesses and obtain appropriate samples (serum and CSF) for diagnostic testing.

Acknowledgments: We thank Frank Matteo (Health Officer), Kay Francoer, Jeff Langlieb, and Donna Studrawa (Public Health Nurse) at the Kenosha County Division of Public Health; Julie Willems Van Dijk (Health Officer) and Ruth Marx (Public Health Nurse) at the Marathon County Health Department; Margaret Nash (Health Officer) at the Rusk County Department of Health and Human Services for their assistance in epidemiologic investigations; Robert Lanciotti, Amanda Panella, Janeen Laven, and Olga Kosoy at the Arboviral Diagnostic Laboratory, CDC; Toyalynn Chassee at the Associated Regional and University Pathologists Laboratories, Salt Lake City, Utah; and Jennifer Meece at the Marshfield Laboratories, Marshfield, Wis. We thank Julie Brockman, Michael Doering, Deborah Upperman, and Mei Chen at the Wisconsin State Laboratory of Hygiene, Madison, Wis, for their assistance in laboratory testing; and Kristin Hardy, Tom Haupt, Rick Heffernan, Jim Kazmierczak, Carrie Nielsen, and Lorna Will, Bureau of Communicable Diseases, Wisconsin Division of Public Health, for critical review and providing research and technical support. We thank all physicians, infection control professionals, nurses, and customer service staffs who were involved with the management of the patients or assisted with this investigation.

Funding/Support: None declared.

Financial Disclosures: None declared.

REFERENCES

1. Calisher CH. Medically important arboviruses of the United States and Canada. *Clin Microbiol Rev.* 1994;7:89-116.
2. Gholam BIA, Puksa S, Provias JP. Powassan encephalitis: a case report with neuropathology and literature review. *CMAJ.* 1999;161:1419-1422.
3. Centers for Disease Control and Prevention. Outbreak of Powassan encephalitis—Maine and Vermont, 1999-2001. *MMWR.* 2001;50:761-764.
4. Ralph ED. Powassan encephalitis. *CMAJ.* 1999;161:1416-1417.
5. Artsob H. Powassan encephalitis. In: Monath TP, ed. *The Arboviruses: Epidemiology and Ecology.* Boca Raton, FL: CRC Press, 1988:29-49.
6. Hinten SR, Beckett GA, Gensheimer KF, et al. Increased recognition of Powassan encephalitis in the United States, 1999-2005. *Vector-borne Zoonotic Dis.* 2008;8:733-740.
7. Minnesota Department of Health Bug Bytes 2008;9. First case of Powassan encephalitis ever in Minnesota. <http://www.health.state.mn.us/divs/idepc/newsletters/bugbytes/0805bb.html#1>. Accessed February 24, 2010.
8. Ebel GD, Spielman A, Telford SR, III. Phylogeny of North American Powassan virus. *J Gen Virol.* 2001;82:1657-1665.
9. Ebel GD, Foppa I, Spielman A, Telford SR, III. A focus of deer tick virus transmission in the northcentral United States. *Emerg Infect Dis.* 1999;5:570-574.
10. Brackney DE, Nofchissey RA, Fitzpatrick KA, Brown IK, Ebel GD. Stable prevalence of Powassan virus in *Ixodes scapularis* in Northern Wisconsin focus. *Am J Trop Med Hyg.* 2008;79:971-973.
11. Centers for Disease Control and Prevention. Nationally notifiable infectious conditions, United States 2010. <http://www.cdc.gov/ncphi/diss/nndss/phs/infdis2010.htm>. Accessed March 11, 2010.
12. Wisconsin Department Health Services. 2008 Disease Reporting. <http://dhs.wisconsin.gov/communicable/diseasereporting/>. Accessed February 24, 2010.
13. Centers for Disease Control and Prevention. 2004 case definition for neuroinvasive and non-neuroinvasive domestic arboviral diseases. http://www.cdc.gov/ncphi/diss/nndss/print/arboviral_current.htm. Accessed February 24, 2010.
14. Centers for Disease Control and Prevention. Epidemic/epizootic West Nile virus in the United States: guidelines for surveillance, prevention, and control. 3rd rev. 2003. <http://www.cdc.gov/ncidod/dvbid/westnile/resources/wnv-guidelines-aug-2003.pdf>. Accessed February 24, 2010.
15. Reimann CA, Hayes EB, DiGiuseppi C, et al. Epidemiology of neuroinvasive arboviral disease in the United States, 1999-2007. *Am J Trop Med Hyg.* 2008;79:974-979.
16. Centers for Disease Control and Prevention. Confirmed and probable Powassan neuroinvasive disease cases, human, United States, 2001-2008, by state (as of April 7, 2009). http://www.cdc.gov/ncidod/dvbid/arbor/pdf/POW_DOC.pdf. Accessed February 24, 2010.
17. Minnesota Department of Health, News Release: Two more diseases from ticks found in Minnesota. June 29, 2009. <http://www.health.state.mn.us/news/pressrel/2009/ticks072909.html>. Accessed February 24, 2010.
18. Centers for Disease Control and Prevention. False-positive results with a commercially available West Nile virus immunoglobulin M assay—United States, 2008. *MMWR.* 2008;58:458-460.
19. Centers for Disease Control and Prevention. Diagnosis and management of tickborne rickettsial diseases: Rocky Mountain spotted fever, ehrlichioses, and anaplasmosis—United States. *MMWR.* 2006;55:1-27.
20. Suss J. Tick-borne encephalitis in Europe and beyond—the epidemiological situation as of 2007. *Euro Surveill.* 2008;13.
21. Telford SR, Armstrong PM, Katavolos P, et al. A new tick-borne encephalitis-like virus infecting New England deer ticks, *Ixodes dammini*. *Emerg Infect Dis.* 1997;3:165-170.
22. Beasley DWC, Suderman MT, Holbrook MR, Barrett ADT. Nucleotide sequencing and serologic evidence that the recently recognized deer tick virus is a genotype of Powassan virus. *Virus Res.* 2001;79:81-89.
23. Kuno G, Artsob H, Karabatsos N, Tsuchiya KR, Chang GJ. Genomic sequencing of deer tick virus and phylogeny of Powassan-related viruses of North America. *Am J Trop Med Hyg.* 2001;65:671-676.
24. Tavakoli NP, Wang H, Dupuis M, et al. Fatal case of deer tick virus encephalitis. *N Engl J Med.* 2009;360:2099-2107.
25. Ebel GD, Kramer LD. Short report: duration of tick attachment required for transmission of Powassan virus by deer ticks. *Am J Trop Med Hyg.* 2004;71:268-271.